Residents
inRadiology

# Complex Iatrogenic Esophageal Injuries: An Imaging Spectrum

Rachna Madan[1]
Ryan James Bair
Jeffrey Forris Beecham Chick

**Keywords:** contrast-enhanced esophagogram, endoscopic procedures esophagus, esophageal surgeries, iatrogenic esophageal injuries

DOI:10.2214/AJR.14.12476

Received December 22, 2013; accepted after revision June 24, 2014.

[1]All authors: Department of Radiology, Division of Thoracic Imaging, Brigham and Women's Hospital, Harvard Medical School, 75 Francis St, Boston, MA 02115. Address correspondence to R. Madan (rmadan@partners.org).

**WEB**
This is a web exclusive article.

*AJR* 2015; 204:W116–W125

0361–803X/15/2042–W116



## Key Educational Objectives and Key Points

- Increases in endoscopic procedures and esophageal surgeries have resulted in iatrogenic injuries becoming the most common cause of esophageal injuries.
- Although iatrogenic injuries are seen in a predictable clinical setting and history of a recent procedure may be present, frequently initial imaging may show no abnormality. Repeating radiographic studies using oral contrast agents in cases with high clinical suspicion is paramount in identifying esophageal injuries.
- In patients with initially negative esophagograms, CT plays a central role by revealing nontransmural perforations, sentinel pneumomediastinum, or localized mediastinitis.
- Early use of MDCT is key to identifying esophageal injuries secondary to stents and hardware as well as for evaluation of associated vascular complications and unique conditions such as atrioesophageal fistulas.

Complex esophageal injuries comprise a heterogeneous group of injuries with varied clinical and radiographic presentations requiring a high clinical index of suspicion for effective management. Early and accurate diagnosis and treatment of esophageal injuries are critical, because failure to recognize these entities may lead to potentially life-threatening complications. Radiographic evaluations are instrumental in the diagnosis of esophageal injuries, because clinical presentations are often vague and nonspecific. A thorough understanding of radiographic utility and application is necessary to provide an individualized approach to the identification and management of these pathologic processes. The purpose of this article is to provide an overview of the multimodality imaging of iatrogenic esophageal injuries and to discuss radiographic identification, diagnosis, and subsequent management.

## Disease Epidemiology

Esophageal injuries are classified into two broad subcategories: iatrogenic and noniatrogenic. Iatrogenic injuries represent more than half of all cases and have been reported to represent as many as 59% of cases, with endoscopic injury being the most common cause [1]. Although the relative incidence of esophageal injury during endoscopy is low (< 0.04%), because of its overall prevalence, it represents the most common cause of iatrogenic esophageal injury [2]. Noniatrogenic esophageal injuries are most commonly spontaneous perforations occurring after foreign body ingestion (15% of cases), food impaction or vomiting (12% of cases), and trauma (9% of cases) [1]. The average mortality rate is 19% for iatrogenic esophageal injury, compared with 36% for noniatrogenic causes. This difference in mortality results from the subacute nature of many noniatrogenic injuries leading to a delay in diagnosis and treatment [3].

## Pathophysiologic Basis: Anatomy and Predisposition to Injury

The esophagus is located in the prevertebral mediastinum and is subdivided into four anatomic regions: cervical, thoracic, lower thoracic-esophageal junction, and abdominal (Table 1). A number of factors predispose the esophagus to injury, including its close approximation to extrinsic structures at the level of the cricopharyngeal muscle, left mainstream bronchus, aortic arch, and diaphragmatic hiatus [4]. In addition, its location in close proximity to cervical and intrathoracic organs, including the thyroid, trachea, aorta, and spine, place the esophagus at increased risk secondary to disease processes and surgeries involving these adjacent organs. Beyond anatomic considerations, the esophagus has a relatively poor vascular supply, heightening the probabili-

**TABLE 1: Anatomy and Pathophysiology of Three Different Types of Iatrogenic Esophageal Injury**

| Injury Classification | Piercing | Shearing and Bursting | Thinning and Weakening |
|---|---|---|---|
| Time of onset | Immediate | Immediate | Delayed (5–7 days) |
| Physiologic mechanism | Areas of physiologic narrowing (pyriform fossa, aortic arch, gastroesophageal junction) | Traction along longitudinal axis with radial forces | Necrosis secondary to pressure or inflammatory processes |
| Procedures implicated | Direct injury from tip of instrument, diverticula formation | Dilation of strictures and lower esophageal sphincter | Sclerotherapy of varices, use of transesophageal echo probe, tumor palliation using thermal techniques |

ty of injury and pressure necrosis. Further increasing its vulnerability, the esophagus lacks a serosal covering, leaving little to no barrier between esophageal contents, the mediastinum, and the pleural cavity after an esophageal injury, leading to high morbidity and mortality [5].

## Esophageal Injury Classification

### *Mechanism and Cause*

Esophageal injury may be categorized mechanistically as extraluminal or intraluminal. The extraluminal classification includes processes originating outside the esophagus, including penetrating blunt trauma and surgery involving adjacent organs. The intraluminal classification encompasses processes within the esophagus itself, including instrumentation, barotrauma, and foreign body ingestion [6].

Further subclassifications characterize injuries as spontaneous versus traumatic or iatrogenic. Spontaneous injuries, often subacute in nature, may have variable presentations and ambiguous clinical courses; such uncertainties may lead to delays in diagnosis and treatment [7]. Dichotomously, traumatic and iatrogenic injures usually present acutely or in a known clinical setting after a procedure (Table 2). The diagnosis and treatment of these causes is more predictable because of the defined nature of their presentations [8].

### *Location or Depth of Injury*

Identifying the depth and associated anatomic location of the esophageal injury is crucial, because medical management is determined by these factors. Esophageal injuries can be classified as nontransmural or transmural after radiographic studies using oral contrast agents. Nontransmural injuries are associated with incomplete wall disruption with small collections of contrast agent adjacent to the esophageal wall. Nontransmural injury can further be subdivided into linear tears with mucosal disruption only (e.g., Mallory-Weiss tears), submucosal dissection and intramural hematoma, and mucosal laceration or tears leading to localized outpouching or diverticula. Transmural injury is complete esophageal rupture with free contrast agent extravasation into the mediastinum, subphrenic, or pleural space [9].

## Radiologic Evaluation

When beginning radiographic evaluation for suspected esophageal injury, an understanding of the patient's clinical history, risk factors, and physical examination findings is requisite. Clinical information will provide insight into the size, location, time since suspected injury, and presence of contamination [10]. This information may provide a diagnostic road map and help in the identification of potentially life-threatening conditions.

### *Radiographs*

Radiographic evaluation should begin with a lateral neck radiograph in cases of suspected cervical esophageal injury and may reveal air in the prevertebral fascial planes before it is detected with chest radiography [11]. In cases of suspected lower esophageal injury, an upright and lateral chest radiograph should be obtained. The Meckel triad of subcutaneous emphysema, chest pain, and vomiting is positive in fewer than 50% of cases of esophageal perforation with radiography. Patient outcomes after esophageal injury are time dependent; hence, any delay in obtaining a radiographic assessment should be avoided. If initial imaging findings are negative, further radiographic evaluation should continue because radiographic evidence of mediastinal emphysema is highly variable, although by 12 hours radiographic abnormalities are observed in 75% of patients with esophageal rupture [7, 12]. The most common findings include mediastinal emphysema, mediastinal widening, pleural effusion, and hydropneumothorax [12] (Fig. 1). The V sign described by Naclerio [13] has been found in patients with esophageal rupture and represents pneumomediastinum outlining the medial left hemidiaphragm and left lower lateral mediastinum.

Pleural effusions may rapidly develop; midesophageal perforations frequently lead to right-sided effusion, whereas distal esophageal perforations are associated with left-sided effusions. Pleural fluid analysis may show elevated amylase, food particles, or a pH less than 6.0, all of which are considered suspicious for esophageal rupture [6].

### *Contrast-Enhanced Esophagogram*

Contrast-enhanced esophagogram is frequently used as the initial imaging modality because of its superior delineation and identification of esophageal perforation [14] (Fig. 2). Although it is the reference standard, it has a less than 10% false-negative rate [15], which may be secondary to inflammation and edema at the site of injury.

**TABLE 2: Surgical and Nonsurgical Instrumentation Associated With Esophageal Injuries**

| Nonsurgical Procedures | Surgical Procedures |
|---|---|
| Nasogastric tube placement | Esophagectomy |
| Endoscopic removal of foreign bodies | Nissen fundoplication |
| Endoscopic ultrasound | Esophageal perforation repair |
| Esophageal dilation and stenting | Esophageal myotomy |
| ERCP | Surgical removal of esophageal foreign bodies |
| Endoscopic radiofrequency ablation for cardiac diseases | Surgical procedures close to esophagus (e.g., diskectomy and aortic stent-graft placement) |

Two types of oral contrast agents, water-soluble iodinated high-osmolality contrast media (e.g., diatrizoate meglumine, Gastrografin, Bracco Diagnostics) and barium sulfate, were historically used in esophagography both with accompanying positive and negative features. Diatrizoate meglumine is water soluble and rapidly absorbed, allowing additional imaging examinations if required. However, because of its hyperosmolar nature, when aspirated, it can lead to pulmonary edema [16]. In addition, it extravasates in only 50% and 80% of cervical and thoracic or abdominal perforations, respectively [17]. Barium sulfate has a higher density with improved mucosal adherence, allowing improved diagnostic accuracy compared with water-soluble iodinated high-osmolality contrast agents, identifying 60% and 90% of cervical and thoracic or abdominal perforations, respectively [18]. This improved accuracy comes with some drawbacks because barium sulfate is not as rapidly absorbed as water-soluble high-osmolality contrast agents, making additional imaging examinations challenging. Furthermore, extravasation of barium sulfate can be associated with inflammatory reactions and the possibility of subsequent fibrosing mediastinitis and granuloma formation [19]. Owing to the possible adverse effects and unwanted imaging effects associated with these agents, more expensive nonionic water-soluble (iohexol, Omnipaque 240, GE Healthcare) or low-osmolar water-soluble (metrizamide) contrast agents are now being used more frequently [20]. These agents are also not without their drawbacks. They have less radiopacity than barium and also diffuse more rapidly into the mediastinum when a leak exists.

Evaluating the entire clinical picture and prior radiologic workup is crucial when selecting an oral contrast agent—specifically, one must evaluate the risk of aspiration and determine which initial diagnostic tests have been negative. When the risk of aspiration is high, ionic water-soluble contrast agents are generally avoided. This is seen in patients who have undergone an esophagectomy and gastric pull-up and lack a lower esophageal sphincter. If initial contrast esophagograms completed with ionic or nonionic water-soluble agents are negative, additional studies should be repeated with barium sulfate if the clinical suspicion of perforation persists. Oral contrast esophagograms that were initially negative may subsequently become positive because of resolution of perilesional edema.

### *CT*

CT is an important imaging tool in the diagnosis of both iatrogenic and noniatrogenic esophageal perforation, the most important added value being that it can also detect nontransumural injuries that are not seen on contrast-enhanced esophagograms. CT is recommended for patients with a high clinical suspicion of esophageal injury after a negative initial esophagogram, critically ill and noncooperative patients, and those patients with penetrating trauma and concomitant vascular and airway injuries. CT can be used to help determine the severity of the esophageal injury and the need for subsequent surgical versus nonsurgical intervention. Importantly, CT allows evaluation of the degree of contamination within the mediastinum, pleural space, and peritoneum. CT findings seen in patients with esophageal injury and perforation include esophageal wall thickening, mucosal hyperemia, and periesophageal gas or fluid collections [21] (Fig. 1). The depth of esophageal injury and extent of sepsis on imaging, as well as time course since initial injury, are key factors in determining further conservative or surgical management (Fig. 2). Although imaging signs may frequently be similar between iatrogenic and noniatrogenic injuries, a higher level of preparedness and predictable site of injury favorably influences morbidity and mortality in iatrogenic injuries.

### *Endoscopy*

Endoscopy is typically not a part of the initial diagnostic armamentarium because there is the possibility to convert small mucosal and submucosal tears into larger tears and perforations during air insufflation [22]. Endoscopy does, however, provide the advantage of direct visualization of the esophageal injury and the ability to fully assess the size, location, and depth of the lesion. Because of the risks associated with this procedure, its clinical applicability is limited to situations of high clinical suspicion of esophageal injury after repeatedly negative CT scans and contrast-enhanced esophagograms, and in those patients with a history of gastroesophageal reflux or peptic ulcer disease [23].

## Iatrogenic Esophageal Injuries

### *Enteric Tube Placement*

Radiographic assessment of nasogastric and postpyloric nasoenteric tubes with chest and abdominal radiographs plays an important role. After ensuring that the tube is not within the airways, the positions of side-hole and end-hole are assessed, and both should be beyond the gastroesophageal junction because fluid can exit a high side-hole into the esophagus. There is a small but nontrivial risk for esophageal or gastric perforation during placement of nasogastric tubes [24] (Fig. 3). This risk of esophageal injury or hematoma after traumatic enteric tube placement is increased in patients with underlying inflammatory or infectious processes (Fig. 4). The mantra of simply pushing the feeding tube should not be followed blindly. Unusual difficulty in the placement of feeding tubes should prompt chest CT evaluation and contrast-enhanced esophagogram to assess for an underlying mass, stricture, or other abnormality. CT evaluation provides important information regarding the size, location, and complexity of the abnormality, which can further guide endoscopic evaluation and intervention.

### *Endoscopic Procedures*

A number of endoscopic procedures are associated with an increased risk of esophageal perforation. Although both sharp and large obstructive foreign bodies have the potential to cause perforation spontaneously, in some cases, esophageal perforation may occur during or after attempts to remove foreign bodies [25] (Fig. 5). This may be due to a combination of factors, including direct mechanical injury or indirect injury secondary to pressure necrosis, ischemia, or devascularization.

Transesophageal echocardiography has the potential to cause esophageal tears at sites of normal anatomic narrowing (posterior wall of the cricopharyngeus muscle at the C5 and C6 levels, or narrowing of the space by prominent cervical osteophytes or above the lower esophageal sphincter) (Fig. 6). Such injuries are thought to be multifactorial in nature, with a combination of contributing factors, including contact pressure by the echocardiography probe, ultrasonic thermal injury, and ischemia during cardiopulmonary bypass, all leading to esophageal compromise [26].

Endoscopic ultrasound is similar to transesophageal echocardiography in having a low complication rate of approximately 1%, with most patients having complications such as biopsy point hemorrhage or bacteremia [27]. There is the potential, however, for more serious complications resulting from this procedure, including localized mediastinitis, severe hemorrhage, and the development of infected pseudoaneurysms [28]. Thrombosed pseudoaneurysms may mim-

ic solid masses or complicated duplication cysts and may inadvertently be biopsied, giving rise to infected pseudoaneurysms, and may also lead to rupture (Fig. 7).

Atrioesophageal fistula is a rare potentially fatal complication of transcatheter radiofrequency ablation for atrial fibrillation. Unfortunately, this complication is often difficult to diagnose because of its variable time of onset (2–41 days) and clinical presentation (fever, neurologic deficits, and polymicrobial bacteremia). Such a variable constellation of symptoms often results in an erroneous diagnosis of endocarditis [29]. On CT evaluation, the presence of intraatrial air or pneumomediastinum is most helpful (Fig. 8A) but is seen in only a small percentage of cases [30]. In most cases, only focal esophageal wall thickening and localized mediastinitis are evident (Figs. 8B and 8C) without direct visualization of a fistula or abnormal extraluminal air. Multiple CT examinations with water-soluble iodinated contrast agents and IV contrast agents may be needed to establish the diagnosis.

### *Spinal Surgery*

The incidence of esophageal perforation after anterior cervical procedures is low (0.1%) but is highest at the Lannier triangle, which is the region formed by the constrictor pharyngeus and cricopharyngeus muscles at the C5 and C6 levels. Within the Lannier triangle, the posterior esophageal mucosa is extremely thin, covered by only a thin fascial layer, thereby increasing the likelihood of injury secondary to instrumentation [31]. Clinical recognition and diagnosis of esophageal perforation after these anterior cervical procedures is highly variable. Many esophageal injures are noted intraoperatively with a recognized mucosal tear, subacutely within 24 hours, or delayed by up to a reported 10 years [31]. Delayed presentation is typically secondary to devascularization resulting from surgical dissection (Fig. 9). These injuries frequently recur after multiple attempts at surgical repair and stenting.

### *Aortic Aneurysm Repair*

Aortoesophageal fistula is a rare and frequently fatal complication occurring relatively early after stent-graft repair of an aortic thoracic aneurysm [32, 33]. Patients with an aortoesophageal fistula may develop mediastinitis, sepsis, or hemorrhage and may present with sudden massive hematemesis coupled with fever. Contrast-enhanced CT may show a new heterogeneous mass between the aorta and esophagus, with or without persistent air entrapment (Fig. 10). Esophagogastroduodenoscopy can be used to directly visualize fistulas, such as large esophageal defects at the level of the implanted aortic stent-graft. Most patients undergoing endovascular aortic aneurysm repair have significant comorbidities precluding open surgical repair and, consequently, are treated conservatively.

### *Esophagectomy, Paraesophageal Hernia Repair, and Pneumonectomy*

Esophagopleural fistulas occur secondary to esophageal perforation and are a result of esophageal surgeries, pneumonectomies, endoscopic procedures, and radiation therapy [34]. In instances of esophagopleural fistulas, a new or increasing pleural effusion or hydropneumothorax may be seen on the involved side (Fig. 11). Contrast-enhanced esophagography using barium sulfate or water-soluble iodinated contrast agents combined with CT with oral contrast agents is used to confirm and localize the fistulous tract (Fig. 12). Esophagopleural fistulas are important to detect and treat promptly because they are associated with empyemas [34].

## Conclusion

Complex esophageal injuries show unpredictability in their clinical and radiographic presentations. Individuals present with variable risk factors, acuity of onset, and degree of esophageal compromise. In addition to understanding the clinical history, thoughtful consideration of the mechanisms and procedures associated with esophageal damage is critical for identification and management of esophageal injuries. Coupling careful clinical analysis with tailored imaging protocols and a high radiographic acumen for subtle findings should be used to effectively diagnose and manage a spectrum of iatrogenic esophageal injuries.

## References


1. Brinster CJ, Singhal S, Lee L, et al. Evolving options in the management of esophageal perforation. *Ann Thorac Surg* 2004; 77:1475–1483
2. Merchea A, Cullinane DC, Sawyer MD, et al. Esophagogastroduodenoscopy-associated gastrointestinal perforations: a single-center experience. *Surgery* 2010; 148:876–880; discussion, 881–882
3. Asensio JA, Chahwan S, Forno W, et al. Penetrating esophageal injuries: multicenter study of the American Association for the Surgery of Trauma. *J Trauma* 2001; 50:289–296
4. Love L, Berkow A. Trauma to the esophagus. *Gastrointest Radiol* 1978; 2:305–321
5. Plott E, Jones D, McDermott D, Levoyer T. A state of the art review of esophageal trauma: where do we stand? *Dis Esophagus* 2007; 20:279–289
6. Wu JT, Mattox KL, Wall MJ. Esophageal perforations: new perspectives and treatment paradigms. *J Trauma* 2007; 63:1173–1184
7. Han SY, McElvein RB, Aldrete JS, Tishler JM. Perforation of the esophagus: correlation of site and cause with plain film findings. *AJR* 1985; 145:537–540
8. Younes Z, Johnson DA. The spectrum of spontaneous and iatrogenic esophageal injury: perforations, Mallory-Weiss tears, and hematomas. *J Clin Gastroenterol* 1999; 29:306–317
9. Young CA, Menias CO, Bhalla S, Prasad SR. CT features of esophageal emergencies. *RadioGraphics* 2008; 28:1541–1553
10. Meyer JP, Barrett JA, Schuler JJ, Flanigan DP. Mandatory vs. selective exploration for penetrating neck trauma. *Arch Surg* 1987; 122:592–597
11. Williamson WA, Ellis FH. Esophageal perforation. In: Taylor MB, Gollan JL, Steer ML, Wolfe MM, eds. *Gastrointestinal emergencies*, 2nd ed. Baltimore, MD: Williams & Wilkins, 1997:31–35
12. Panzini L, Burrell MI, Traube M. Instrumental esophageal perforation: chest film findings. *Am J Gastroenterol* 1994; 89:367–370
13. Naclerio EA. The "v sign" in the diagnosis of spontaneous rupture of the esophagus. *Am J Surg* 1957; 93:291–298
14. White CS, Templeton PA, Attar S. Esophageal perforation: CT findings. *AJR* 1993; 160:767–770
15. Giménez A, Franquet T, Erasmus JJ, Martínez S, Estrada P. Thoracic complications of esophageal disorders. *RadioGraphics* 2002; 22:S247–S258
16. Vallböhmer D, Hölscher AH, Hölscher M, et al. Options in the management of esophageal perforation: analysis over a 12-year period. *Dis Esophagus* 2010; 23:185–190
17. Foley MJ, Ghahremani GG, Rogers LF. Reappraisal of contrast media used to detect upper gastrointestinal perforations: comparison of ionic water-soluble media with barium sulfate. *Radiology* 1982; 144:231–237
18. Buecker A, Wein BB, Neuerburg JM, Guenther RW. Esophageal perforation: comparison of use of aqueous and barium-containing contrast media. *Radiology* 1997; 202:683–686
19. Ginai AZ, ten Kate FJ, ten Berg RG, Hoornstra K. Experimental evaluation of various available contrast agents for use in the upper gastrointestinal tract in case of suspected leakage: effects on mediastinum. *Br J Radiol* 1985; 58:585–592
20. Brick SH, Caroline DF, Lev-Toaff AS, Friedman AC, Grumbach K, Radecki PD. Esophageal disruption: evaluation with iohexol esophagography.

*Radiology* 1988; 169:141–143
21. De Lutio di Castelguidone E, Pinto A, Merola S, Stavolo C, Romano L. Role of spiral and multislice computed tomography in the evaluation of traumatic and spontaneous oesophageal perforation: our experience. *Radiol Med (Torino)* 2005; 109:252–259
22. Pasricha PJ, Fleischer DE, Kalloo AN. Endoscopic perforations of the upper digestive tract: a review of their pathogenesis, prevention, and management. *Gastroenterology* 1994; 106:787–802
23. Horwitz B, Krevsky B, Buckman RF Jr, Fisher RS, Dabezies MA. Endoscopic evaluation of penetrating esophageal injuries. *Am J Gastroenterol* 1993; 88:1249–1253
24. Prabhakaran S, Doraiswamy VA, Nagaraja V, et al. Nasoenteric tube complications. *Scand J Surg* 2012; 101:147–155
25. Peng A, Li Y, Xiao Z, Wu W. Study of clinical treatment of esophageal foreign body-induced esophageal perforation with lethal complications. *Eur Arch Otorhinolaryngol* 2012; 269:2027–2036
26. Hilberath JN, Oakes DA, Shernan SK, Bulwer BE, D'Ambra MN, Eltzschiq HK. Safety of transesophageal echocardiography. *J Am Soc Echocardiogr* 2010; 23:1115–1127
27. Adler DG, Jacobson BC, Davila RE, et al. ASGE guideline: complications of EUS. *Gastrointest Endosc* 2005; 61:8–12
28. Eloubeidi MA, Tamhane A, Lopes TL, Morgan DE, Cerfolio RJ. Cervical esophageal perforations at the time of endoscopic ultrasound: a prospective evaluation of frequency, outcomes, and patient management. *Am J Gastroenterol* 2009; 104:53–56
29. Dagres N, Kottkamp H, Piorkowski C, et al. Rapid detection and successful treatment of esophageal perforation after radiofrequency ablation of atrial fibrillation: lessons from five cases. *J Cardiovasc Electrophysiol* 2006; 17:1213–1215
30. Preis O, Digumarthy SR, Wright CD, Shepard JA. Atrioesophageal fistula after catheter pulmonary venous ablation for atrial fibrillation: imaging features. *J Thorac Imaging* 2007; 22:283–285
31. Patel NP, Wolcott WP, Johnson JP, et al. Esophageal injury associated with anterior cervical spine injury. *Surg Neurol* 2008; 69:20–24
32. Isasti G, Gómez-Doblas JJ, Olalla E. Aortoesophageal fistula: an uncommon complication after stent-graft repair of an aortic thoracic aneurysm. *Interact Cardiovasc Thorac Surg* 2009; 9:683–684
33. Eggebrecht H, Mehta RH, Dechene A, et al. Aortoesophageal fistula after thoracic aortic stent-graft placement: a rare but catastrophic complication of a novel emerging technique. *JACC Cardiol Interv* 2009; 2:570–576
34. Chae EJ, Seo JB, Kim SY, et al. Radiographic and CT findings of thoracic complications after pneumonectomy. *RadioGraphics* 2006; 26:1449–1468

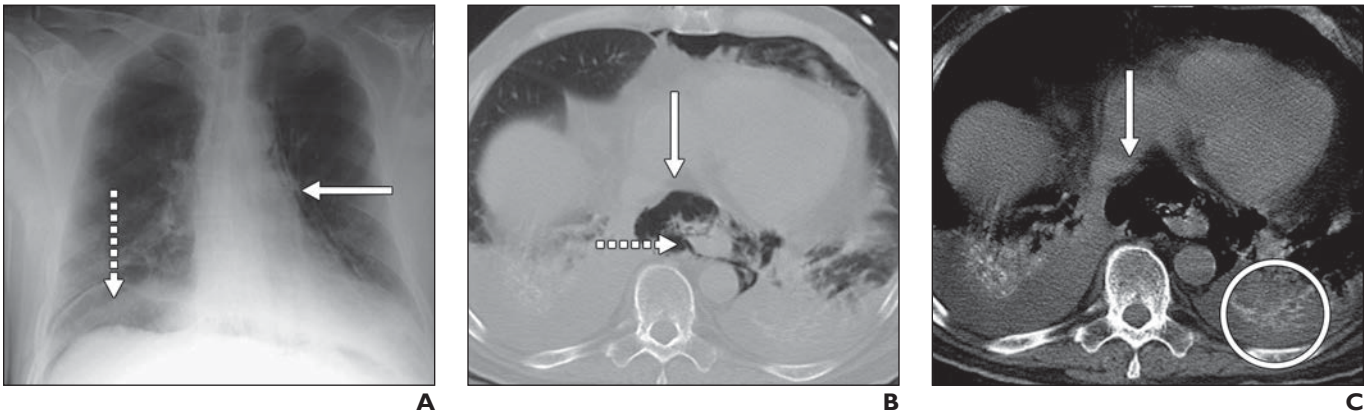


**Fig. 1**—57-year-old man who presented 2 days after upper endoscopy with midback pain, hypotension, and tachycardia concerning for esophageal perforation.
**A,** Portable chest radiograph shows large pneumomediastinum along left cardiac border (*solid arrow*) and pneumoperitoneum (*dashed arrow*).
**B** and **C,** Transverse CT chest images in lung (**B**) and soft-tissue (**C**) windows confirm pneumomediastinum in posterior mediastinum surrounding lower thoracic esophagus (*solid arrows*, **B** and **C**). Thickening of esophageal wall due to hematoma or esophagitis (*dashed arrow*, **B**) indicates site of injury. Aspirated oral contrast agent is noted in lower lobes (*circle*, **C**) due to associated dysphagia and odynophagia. Extensive pneumomediastinum and pneumoperitoneum indicate large uncontained transmural perforation, which is surgical emergency; 3-cm tear was seen 3 cm above gastroesophageal junction at surgery.

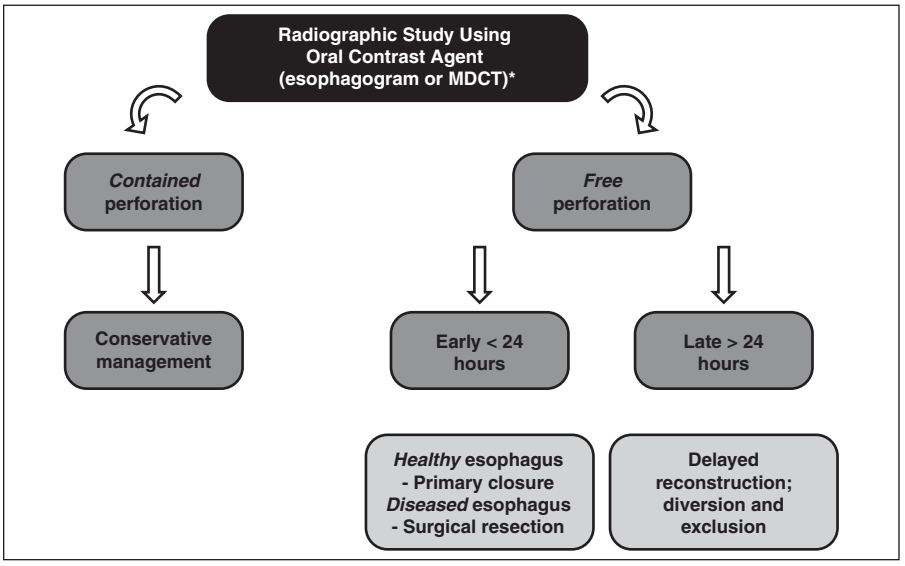


**Fig. 2**—Flow chart showing implications for management according to depth and extent of esophageal injury on imaging. Asterisk denotes that either contrast esophagogram or MDCT using oral contrast agent may be done for initial evaluation. MDCT is preferred if general condition is poor and patient is unable to cooperate and when there is need to quantify contamination in mediastinum and pleural space before surgical intervention.

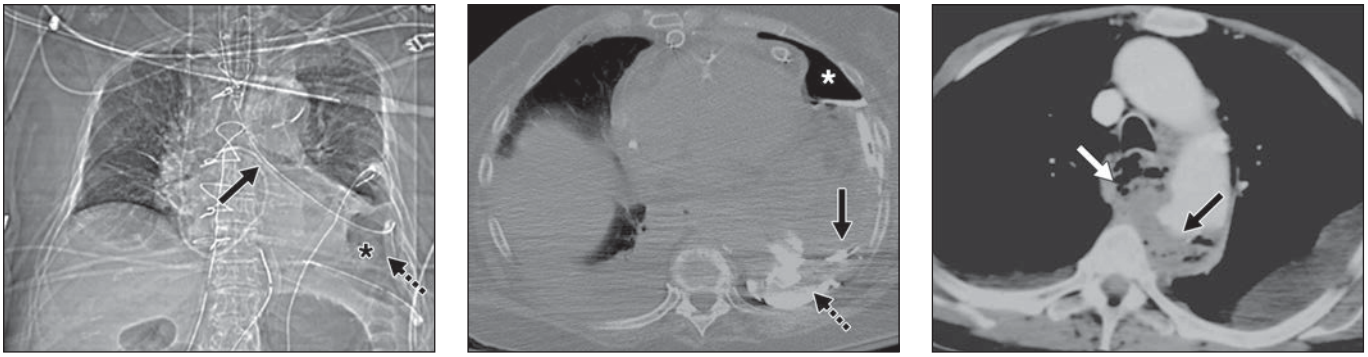


**Fig. 3**—76-year-old man who underwent recent cardiac surgery with complicated postoperative course requiring admission to ICU and nasogastric tube placement.
**A,** Localizer radiograph shows malpositioned nasogastric tube that perforates through esophagus, crosses across left mainstem bronchus (*solid arrow*), and terminates in pleural space (*dashed arrow*). Deep sulcus on left (*asterisk*) indicates basilar pneumothorax secondary to malpositioned line.
**B,** Transverse CT image in bone window shows nasogastric tube terminating in left pleural space (*solid arrow*). Left basilar pneumothorax (*asterisk*) is seen anterior to tube, and dense extravasated oral contrast agent (*dashed arrow*) is noted posteriorly in pleural space.
**C,** Transverse contrast-enhanced CT image obtained few days after perforation shows soft-tissue stranding, foci of gas in mediastinum indicating mediastinitis, and abscess formation (*white arrow*). Focal outpouching of distal aortic arch (*black arrow*) indicates development of mycotic pseudoaneurysm, a potentially life-threatening complication after iatrogenic esophageal perforation. Nasogastric tube was removed.

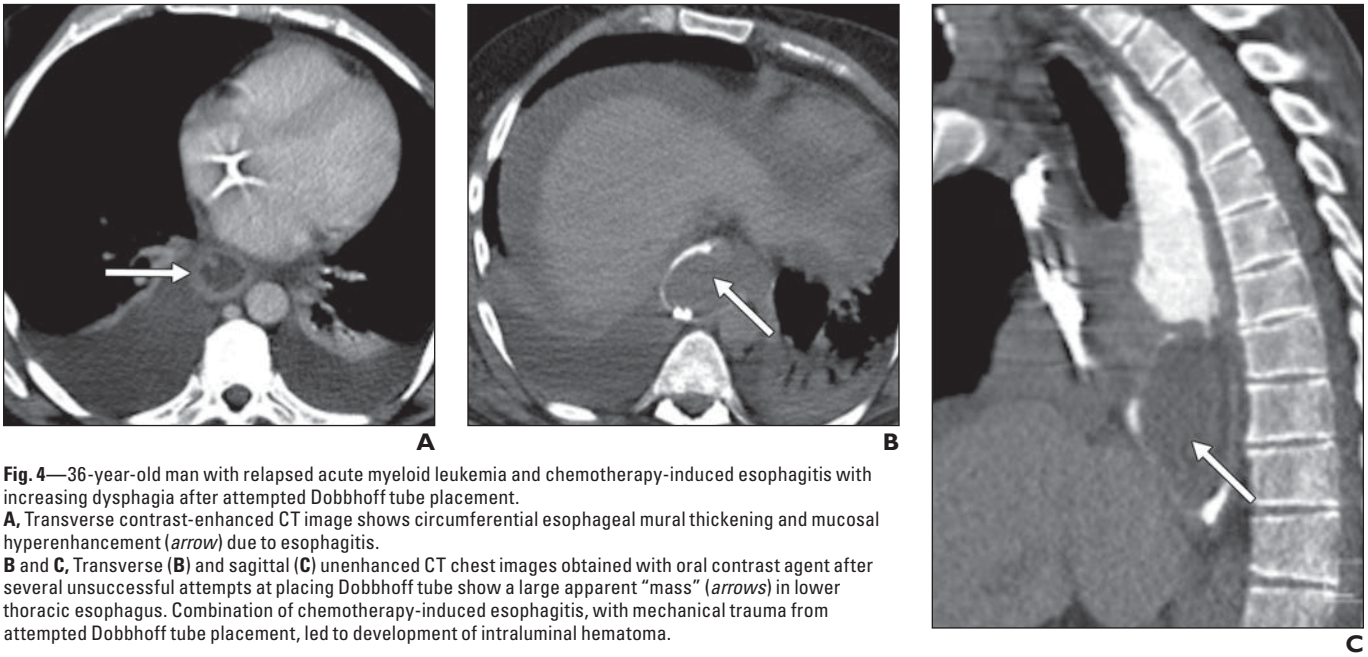


**Fig. 4**—36-year-old man with relapsed acute myeloid leukemia and chemotherapy-induced esophagitis with increasing dysphagia after attempted Dobbhoff tube placement.
**A,** Transverse contrast-enhanced CT image shows circumferential esophageal mural thickening and mucosal hyperenhancement (*arrow*) due to esophagitis.
**B** and **C,** Transverse (**B**) and sagittal (**C**) unenhanced CT chest images obtained with oral contrast agent after several unsuccessful attempts at placing Dobbhoff tube show a large apparent "mass" (*arrows*) in lower thoracic esophagus. Combination of chemotherapy-induced esophagitis, with mechanical trauma from attempted Dobbhoff tube placement, led to development of intraluminal hematoma.

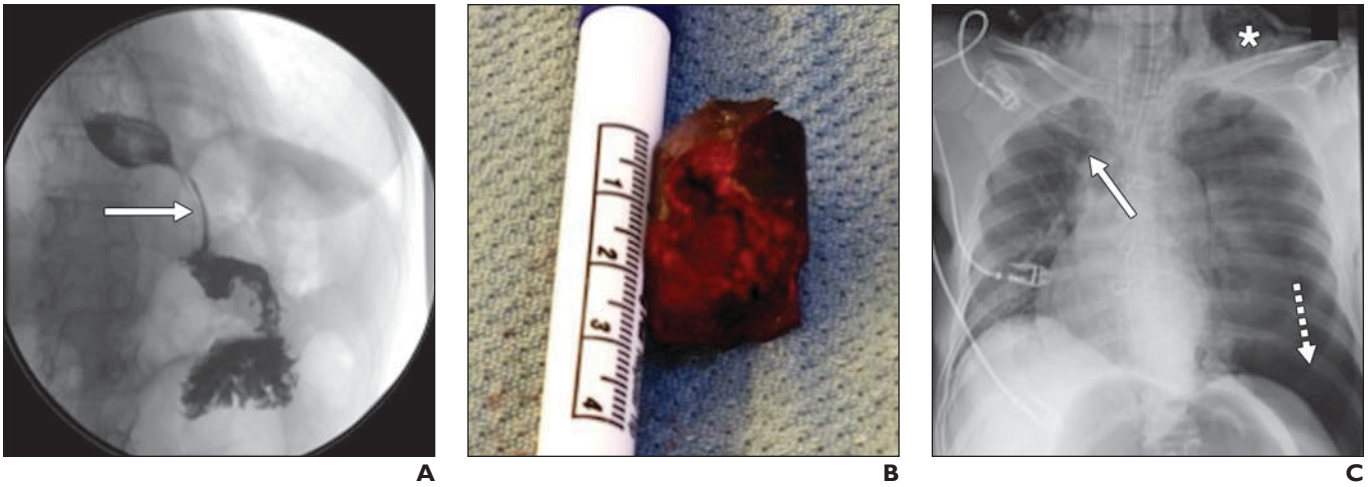


**Fig. 5**—56-year-old woman with esophageal perforation after endoscopic removal of impacted food bolus.
**A,** Upper gastrointestinal series using water-soluble iodinated contrast agent shows marked and persistent narrowing (*arrow*) of contrast column in distal thoracic esophagus at site of impacted food bolus. No leak was seen.
**B,** Large impacted hot dog was removed in one piece.
**C,** Intraoperative radiograph shows left-sided tension pneumothorax (*dashed arrow*), moderate-to-severe pneumomediastinum (*solid arrow*), and subcutaneous emphysema (*asterisk*) indicating intraoperative esophageal injury after removal of impacted food bolus.

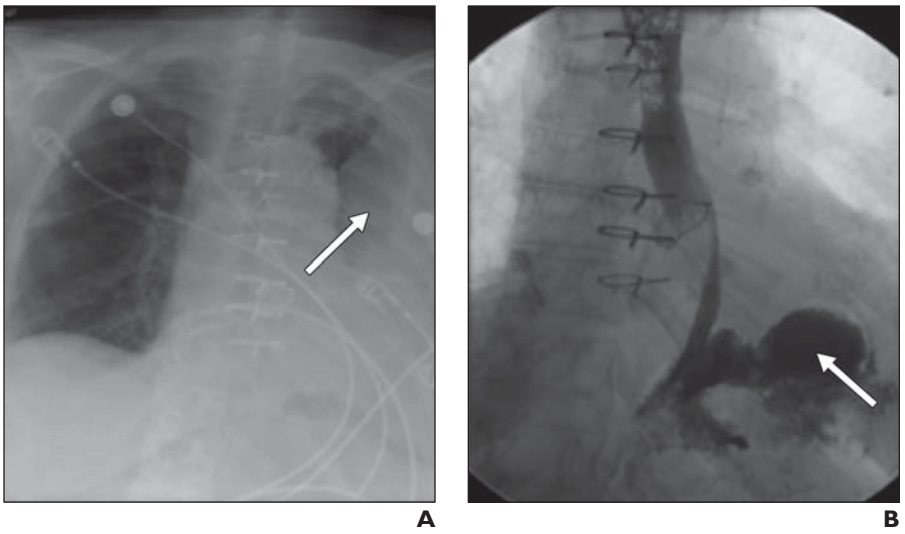


**Fig. 6**—65-year-old man who underwent multiple transesophageal echocardiography examinations during coronary artery bypass surgery and aortic valve replacement.
**A,** Portable chest radiograph obtained 1 week after surgery shows large-volume left pleural effusion (*arrow*). There was also increase in left chest tube output. Pleural fluid analysis revealed elevated amylase and low pH value, which was suggestive of esophageal perforation.
**B,** Esophagogram completed using water-soluble iodinated contrast agent shows free extravasation of oral contrast into left pleural space (*arrow*). Transesophageal echocardiography used to assess cardiac function during cardiac surgery was likely the cause of esophageal perforation. This iatrogenic esophageal injury was relatively delayed in onset (5–7 days after instrumentation) and resulted from combination of ultrasonic thermal injury, ischemia during bypass, and direct probe pressure.

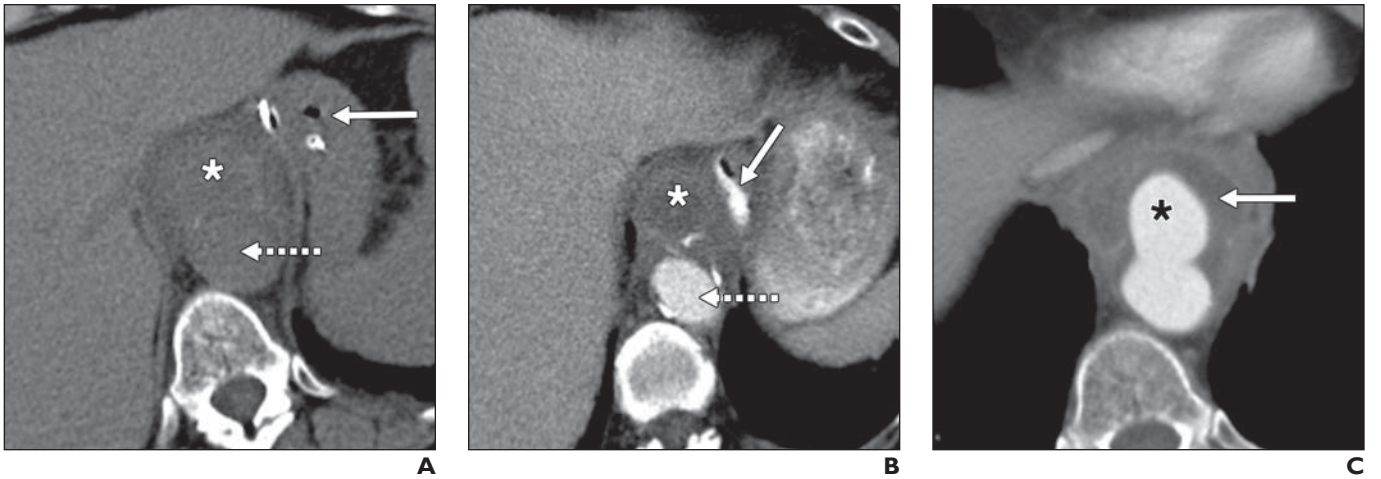


**Fig. 7**—66-year-old woman with increasing back pain and discovery of aortic pseudoaneurysm after endoscopic ultrasound-guided biopsy of paraesophageal mass.
**A,** Preprocedure unenhanced transverse CT image shows high-attenuation retrocrural mass (*asterisk*) in close proximity to esophagus (*solid arrow*) and descending thoracic aorta (*dashed arrow*).
**B,** Preprocedure contrast-enhanced transverse CT angiogram image to rule out vascular cause or pseudoaneurysm shows retrocrural mass (*asterisk*) again closely associated with aorta (*dashed arrow*) and contrast-filled esophagus (*solid arrow*). Rounded mass shows no filling in with IV contrast agent. Differential diagnosis includes thrombosed pseudoaneurysm, neurogenic tumor, leiomyoma, and duplication cyst.
**C,** Postprocedure contrast-enhanced CT image obtained 1 month later shows large saccular pseudoaneurysm (*asterisk*) arising anteriorly from aorta and associated enlarging periaortic hematoma and abscess (*arrow*). Patient underwent urgent repair of infected aortic pseudoaneurysm and replacement with homograft. Endoscopic-guided procedures may result in injury to esophagus and adjacent structures including aorta. In this case, thrombosed aortic pseudoaneurysm developed infection after endoscopic procedure.

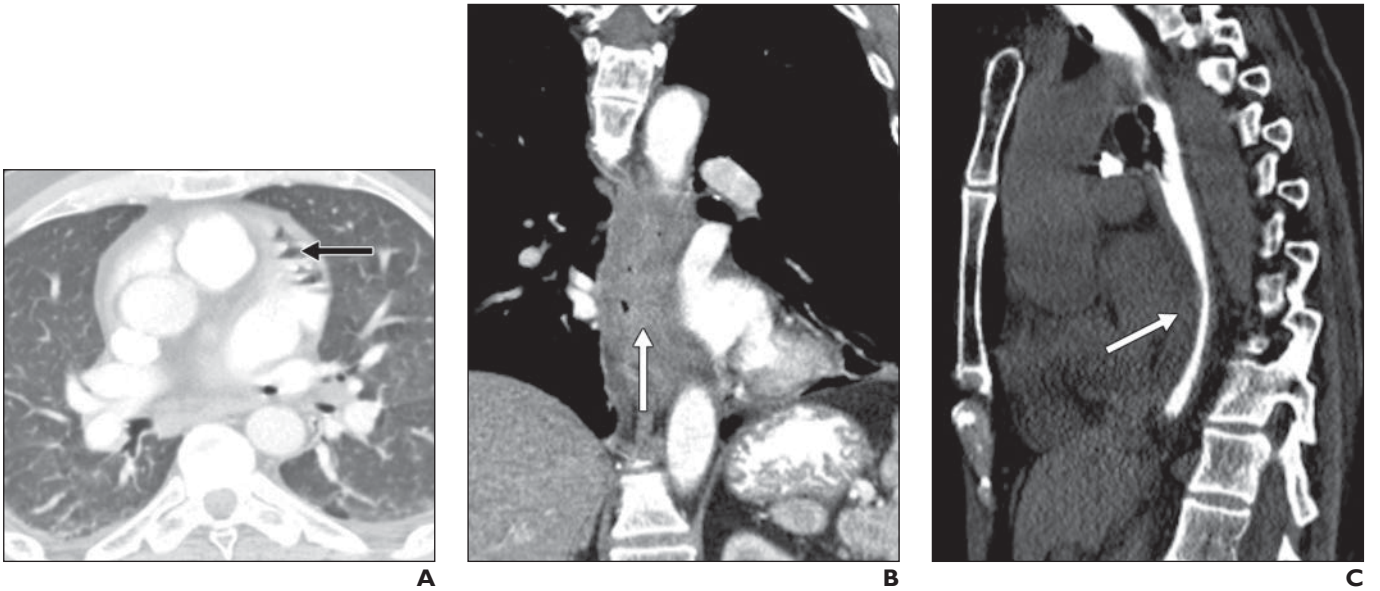


**Fig. 8**—Two patients who underwent transcatheter ablation for atrial fibrillation.
**A,** 59-year-old woman with atrioesophageal fistula after transcatheter ablation of left atrium for atrial fibrillation. Transverse contrast-enhanced chest CT image in lung window shows prominent foci of gas (*arrow*) in left atrium, pulmonary veins, and left atrial appendage concerning for underlying atrioesophageal fistula. (Courtesy of Sharma A and O'Malley Shepard JA, Department of Radiology, Massachusetts General Hospital, Harvard Medical School, Boston, MA)
**B** and **C,** 76-year-old man who underwent ablation for atrial fibrillation. Coronal contrast-enhanced CT (**B**) shows that infiltrative soft tissue is seen in prevertebral mediastinum extending along posterior wall of left atrium. Long segment of esophageal wall is diffusely thickened (*arrow*) and inseparable from adjacent soft tissue. Sagittal CT chest obtained after oral contrast agent administration (**C**) shows circumferential thickening of mid to distal thoracic esophageal wall and narrowing of esophageal lumen (*arrow*). Although no extraluminal leak of oral contrast agent was seen, findings were suspicious for perforation and mediastinitis. Patient underwent thoracotomy, and atrioesophageal fistula was repaired using muscle flap. Proximity of esophageal wall to ablated area may result in injury to esophagus and formation of atrioesophageal fistula. Electroanatomic mapping can help minimize esophageal injury; however, esophageal peristalsis cannot be monitored. Use of IV and water-soluble iodinated oral contrast agents is helpful in establishing diagnosis in cases that do not show air in cardiac chambers. Some patients may need multiple CT scans if initial scans are negative.

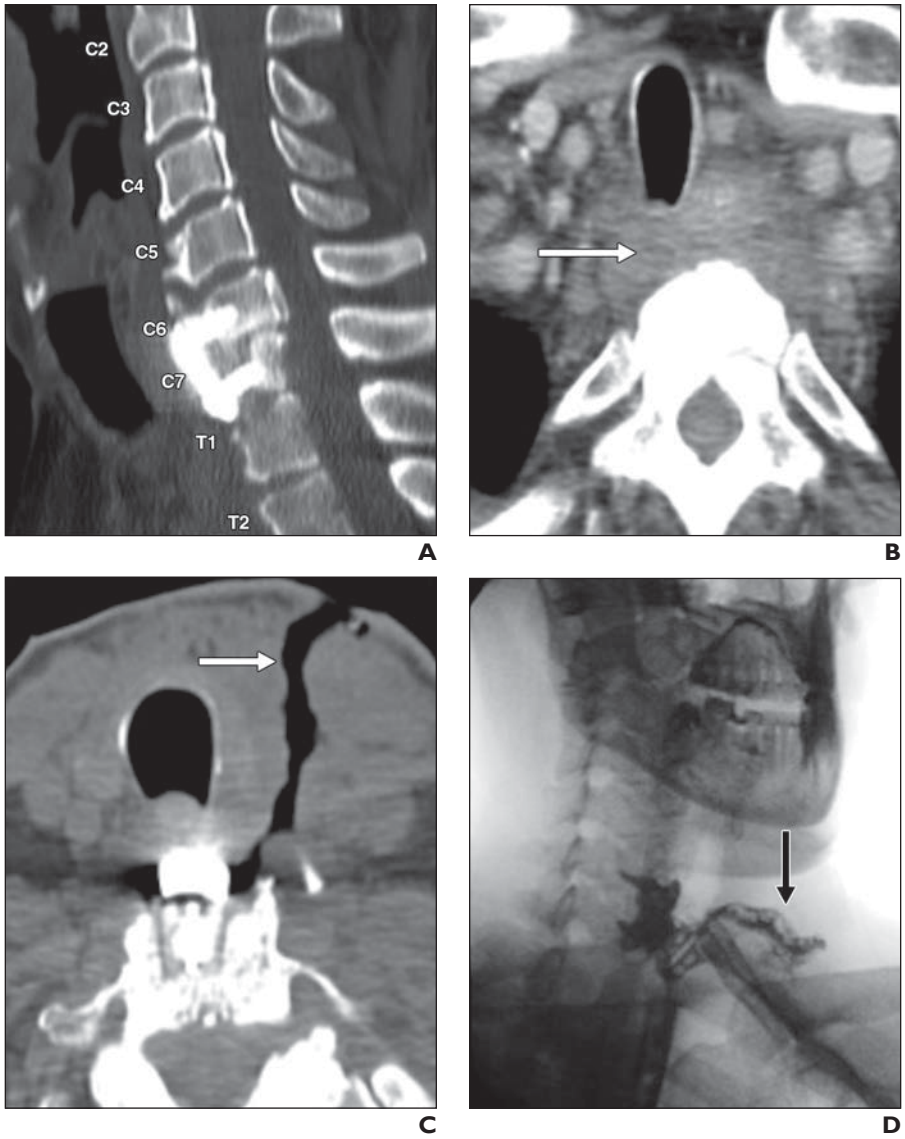


**Fig. 9**—49-year-old man with increasing neck pain and esophagocutaneous fistula after anterior cervical diskectomy with neck dissection.
**A,** Sagittal CT image of neck with bone windows shows loosening and anterior bulging of cervical fusion plate. Plate was surgically removed, and neck dissection was performed to remove adhesions. Postoperative course was complicated by persistent fever and neck tenderness.
**B** and **C,** Transverse CT images obtained few days apart after reoperation show prevertebral soft-tissue thickening suspicious for phlegmon (*arrow*, **B**) and subsequent development of air-filled tract (*arrow*, **C**) in neck, concerning for fistula.
**D,** Barium esophagogram shows esophagocutaneous fistula (*arrow*) and confirms esophageal injury. Esophagus may sustain penetrating injury during surgery or may be devascularized during surgical dissection and subsequently develop delayed ischemic necrosis. These have protracted clinical courses with recurrent fistulas occurring after surgical repairs.

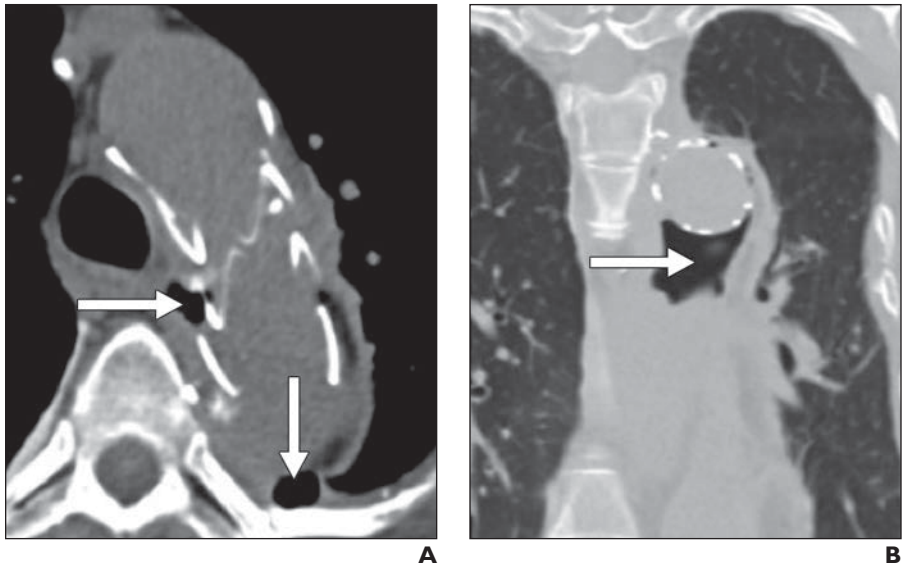


**Fig. 10**—88-year-old woman who underwent repair of type B aortic dissection with postoperative course complicated by hematemesis, hematochezia, and loss of consciousness. Esophagogastroduodenoscopy showed proximal aortoesophageal fistula. Patient underwent emergent repair of fistula requiring aortic metal stent and omental patch repair.
**A,** Transverse unenhanced follow-up CT chest image (history of renal failure) obtained 2 weeks later shows aortic stent-graft and periaortic air foci (*arrows*). These may be postoperative or related to incompletely closed fistula.
**B,** Coronal CT again shows prominent air foci adjacent to site of previously repaired fistula (*arrow*). In absence of fluid collection, stranding, or new symptoms, this was attributed to persistent small fistulous communication. Subsequent endoscopy found persistent small and well-epithelized fistulous connection at 28 cm from incisors extending into periaortic mediastinum. Secondary repair was not attempted because of lack of symptoms, patient age, and comorbidities.

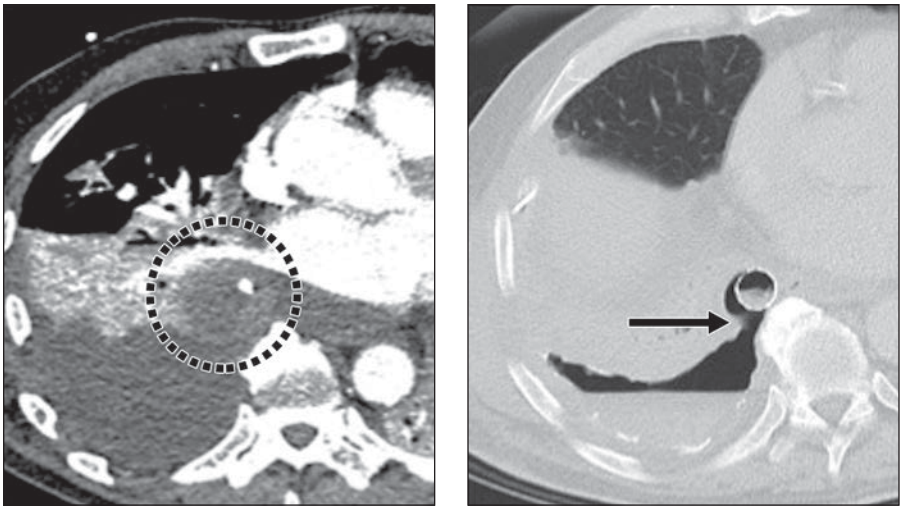


**Fig. 11**—69-year-old man with esophagopleural fistula after recently aborted esophagectomy for advanced stage unresectable esophageal adenocarcinoma.
**A,** Initial postoperative contrast-enhanced transverse CT image shows ballooned-out esophagus and poor enhancement (*circle*), both of which are features of ischemia of esophagus.
**B,** Transverse CT image in lung windows obtained 3 days later shows full-thickness large tear (*arrow*) and esophagopleural fistula. Covered stent used to treat fistula was unsuccessful because of very large size and full thickness of tear. Esophagopleural fistulas are associated with severe empyemas. Early imaging finding is asymmetric wall thinning and focal ballooning of esophagus, whereas in later stages, full-thickness tear is seen.

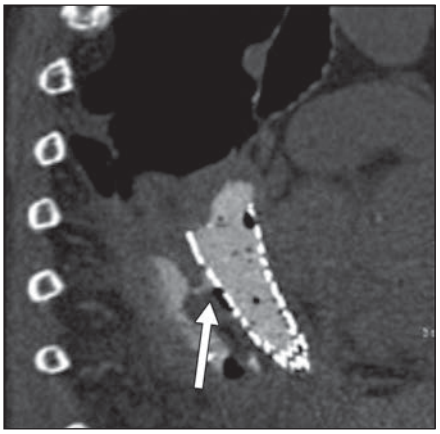

**Fig. 12**—55-year-old man who underwent repair of large paraesophageal hernia and resection of epiphrenic diverticulum complicated by esophageal perforation and esophagopleural fistula. Thin 3-mm curved-planar reconstruction obtained after oral contrast agent administration shows thin fistulous connection (*arrow*) extending from esophagus up to pleural surface, which persists despite covered stent placement. These findings suggest stent malfunction rather than stent slippage. Use of thinner sections, curved-planar reformations, and 3D volume-rendered images increases likelihood of accurate diagnosis in postprocedural situations. Highlighted in this case is that stent malfunction was diagnosed rather than stent misplacement.